



An Introduction to

Uroradiology

دکتر پژمان شادپور

متخصص اورولوژی

فوق تخصص اورولوژی اطفال و لاپاراسکوپی



Hasheminejad Kidney Center



Objectives

□ Must learn:

- Interpretation of normal and grossly pathologic findings on the **KUB** , **IVU** , **VCUG** and **RUG**

□ Better learn:

- GU sonographic image anatomy
- GU CT scan image anatomy

□ Good to learn:

- GU scintigraphic modalities



Prelude

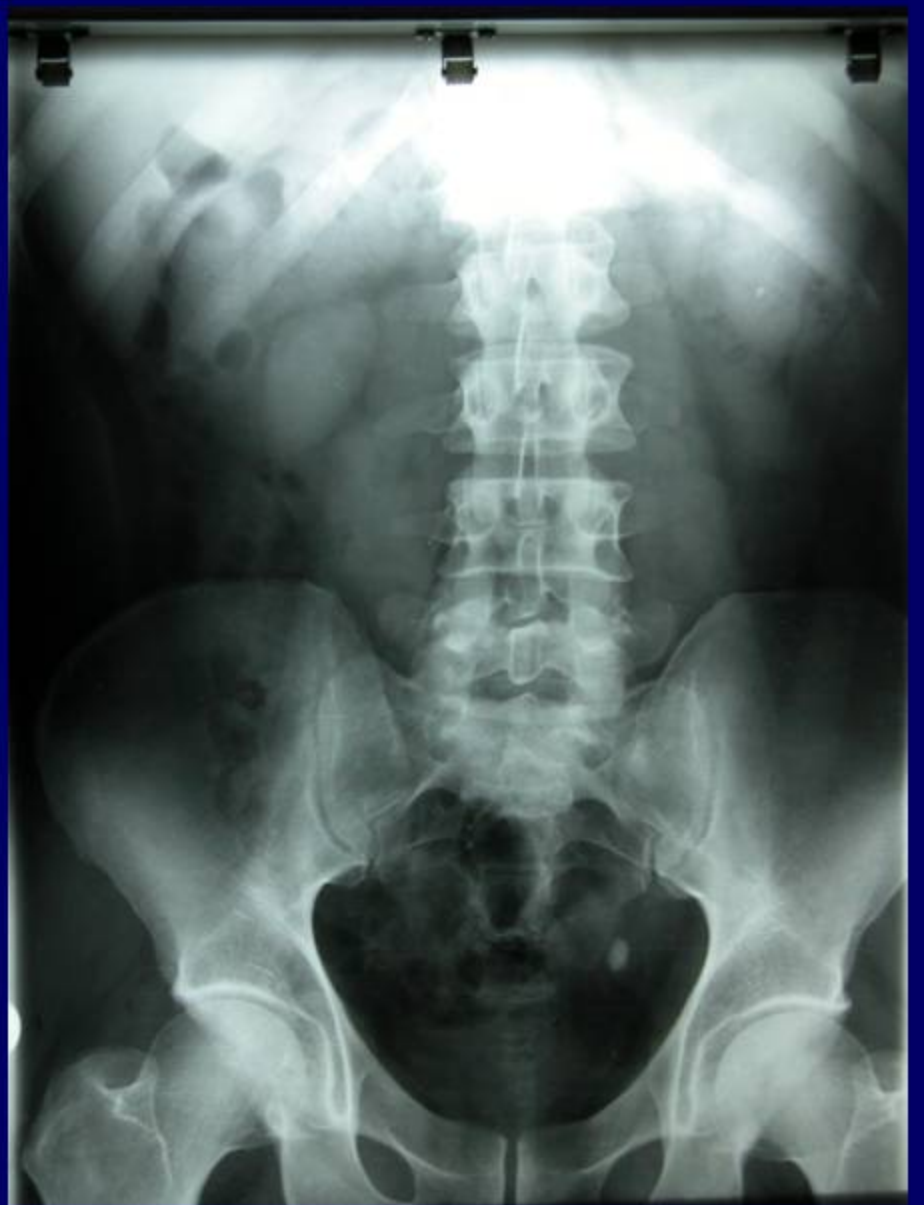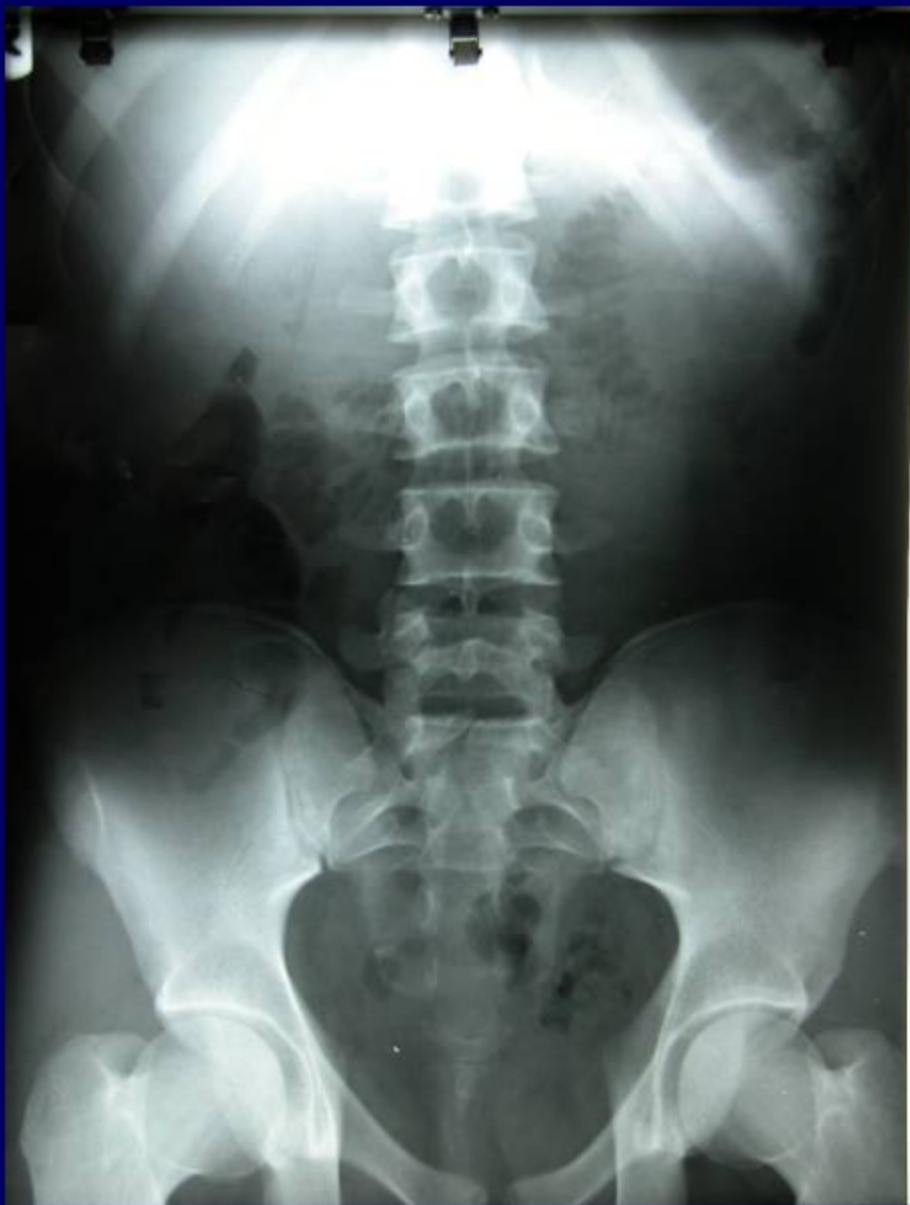- Imaging and Urology are thoroughly integrated : Preop Intraop Postop

- Expanse:
 - Conventional radiology: *Plain, Contrast*
 - Sonography: *S mode, Doppler, Duplex, Contrast*
 - CT scan: *spiral 3D virtual endoscopy*
 - Angiography
 - Scintigraphy
 - (MRU)

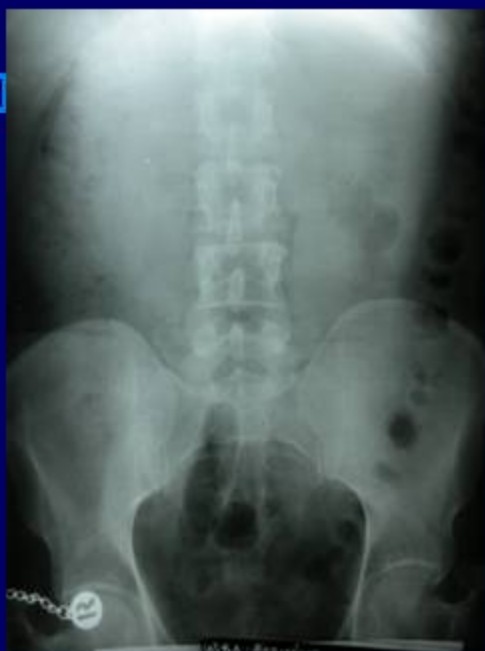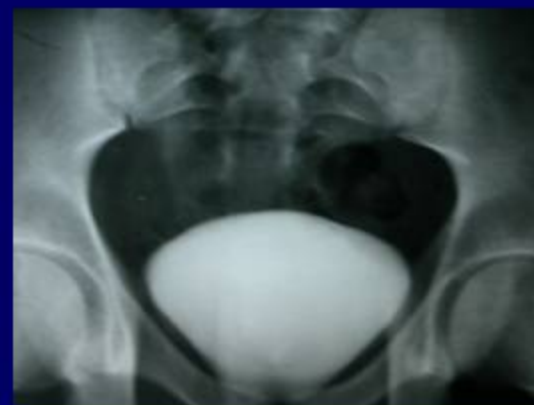

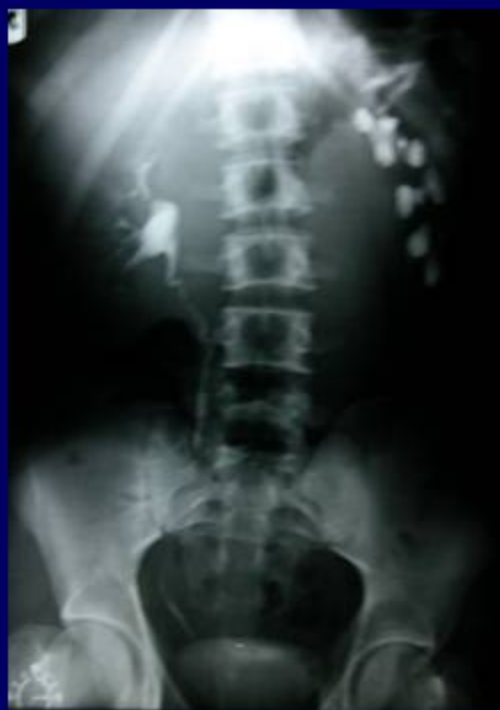
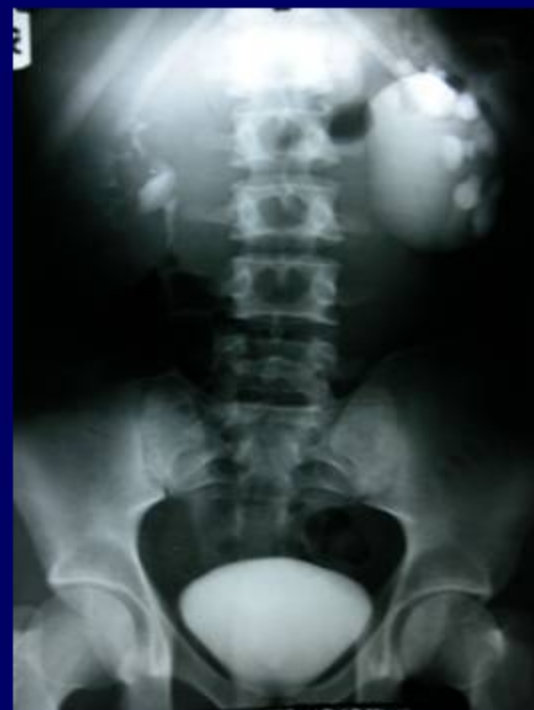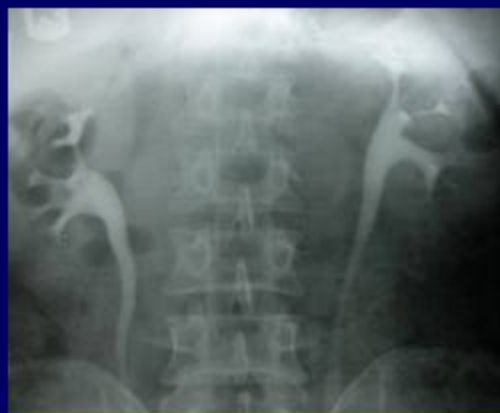KUB

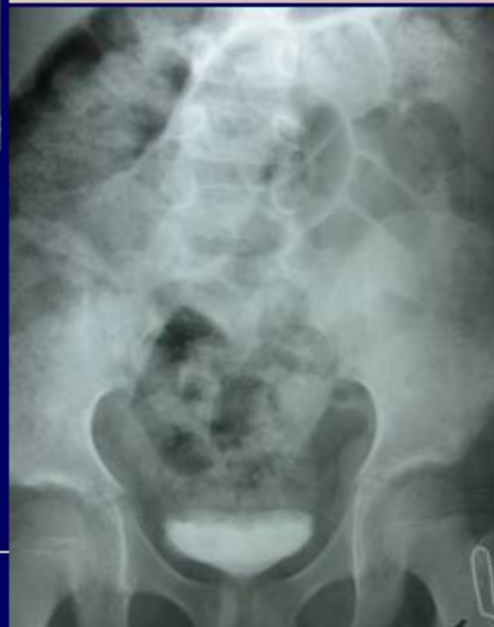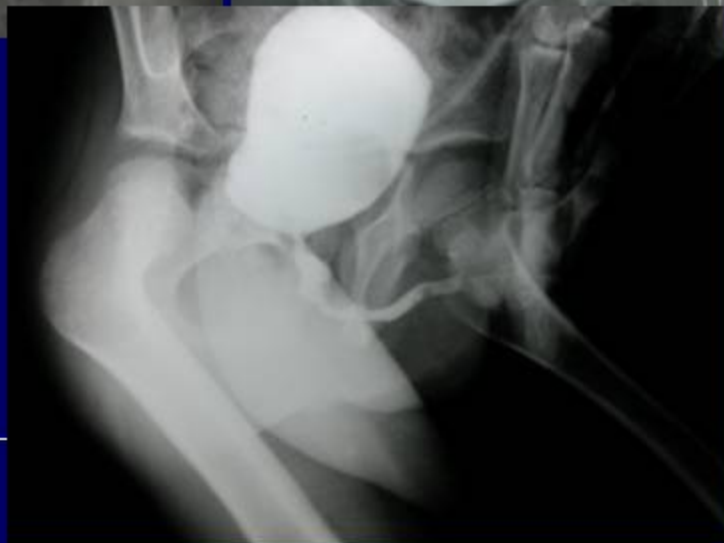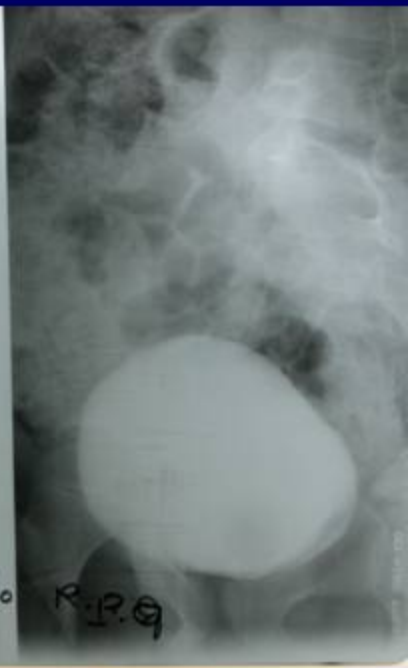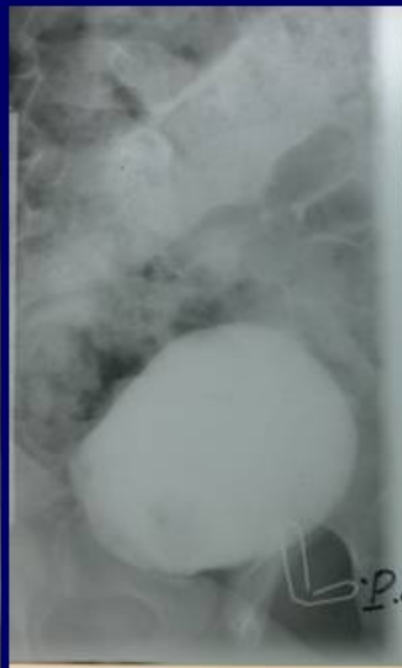
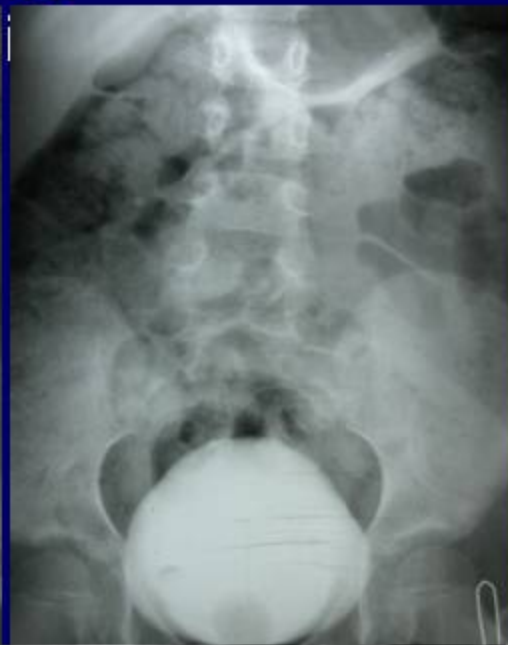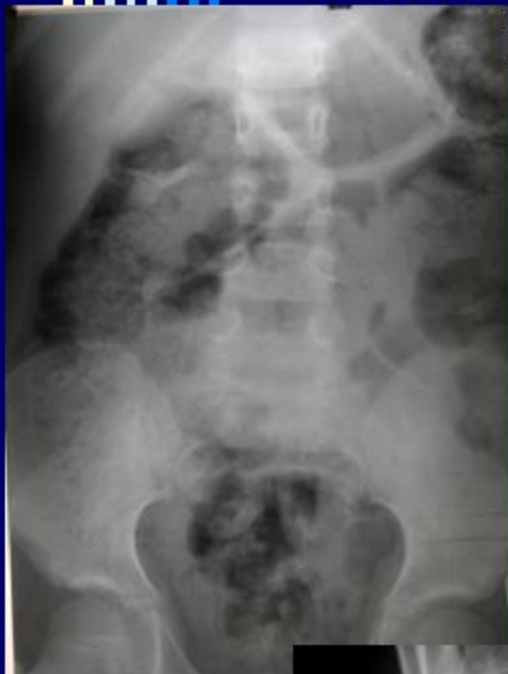- Elective, prepped, supine, limited boundaries
- Ordering
- Interpretation



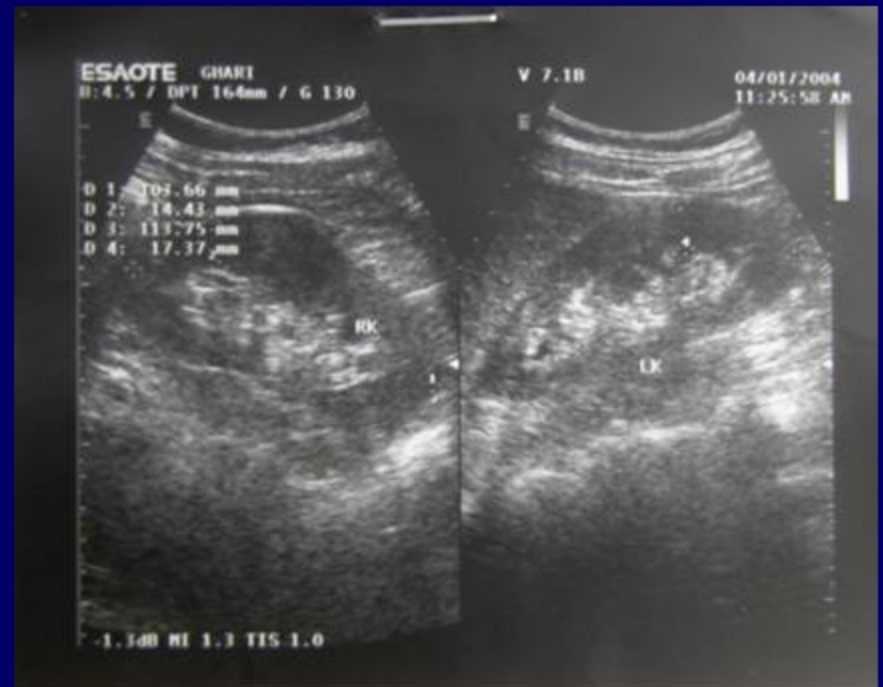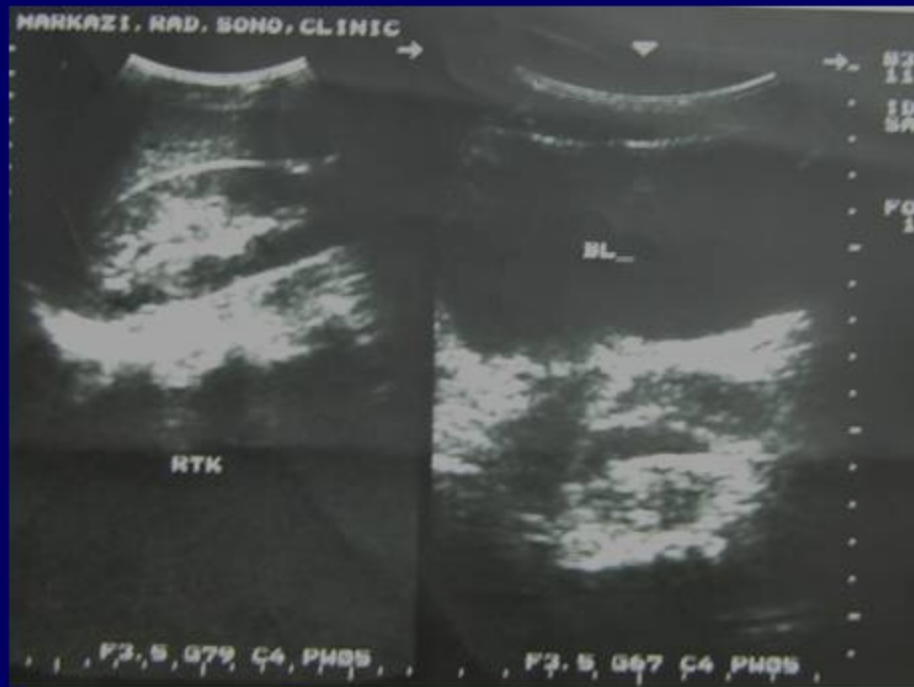IVU

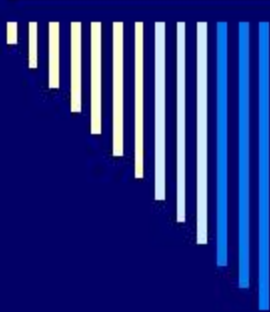

VCUG



SONOGRAPHY





C

